Symbiosis

www.symbiosisonline.org
www.symbiosisonlinepublishing.com

Case Report | Clinical Research in Dermatology: Open Access | Open Access

Atrophying Tinea Versicolor

Sailesh Konda[1]*, Lina Kennedy[2], Mwatsveruka Munhutu[2], Rebat M. Halder[2]

[1]*Department of Dermatology, University of Florida College of Medicine, Gainesville, FL*
[2]*Department of Dermatology, Howard University College of Medicine, Washington, DC 20060*

Received: July 07, 2015; Accepted: November 23, 2015; Published: December 05, 2015

***Corresponding author:** *Department of Dermatology, University of Florida College of Medicine, 4037 NW 86th Terrace, 4th Floor, Gainesville, FL 32606 Tel: 352-594-1942; Fax: 352-594-1926; Email: sailesh.konda@dermatology.med.ufl.edu*

Abstract

A 26-year-old African female, originally from Mali, presented for evaluation of "white spots" on her neck, torso, and upper arms that started one year ago. Several months before the eruption, she had been using a skin-lightening cream, called Perfect White, which contains kojic acid as an active ingredient. After the lesions developed, she stopped using the cream. However, the lesions continued to increase in number with associated pruritus. She denied any systemic symptoms. Physical examination of her chest, abdomen, back, and upper extremities revealed numerous, guttate, depigmented, porcelain-white papules with cigarette paper atrophy, subtle scale, and scattered excoriations. Her neck had hypopigmented irregular macules with subtle scale. Histopathology revealed multiple short hyphae and spores in the stratum corneum and Verhoeff-Van Gieson revealed mild elastolysis consistent with atrophying tinea versicolor. She was started on topical ketoconazole 2% shampoo three times weekly. After her liver function tests returned within normal limits, she received a 2-week course of oral ketoconazole with marked clinical improvement. There have been only 16 reports of atrophying tinea versicolor since 1971. Previous reports document complete resolution of lesions, including atrophy, following courses of oral antifungal therapy.

Keywords: Atrophying; Atrophy; Tinea versicolor; Hypopigmentation; Depigmentation; Kojic acid; Skin of color

Case Report

A 26-year-old African female, originally from Mali, presented for evaluation of "white spots" on her torso, upper arms, and neck of approximately one year duration. Several months before the onset of the eruption, she had been using a skin-lightening cream, called *Perfect White*, which contains kojic acid as an active ingredient. After the lesions developed, she stopped using the skin-lightening cream. However, the lesions continued to increase in number with associated pruritus. She denied any systemic symptoms and her only medication was a daily multivitamin.

Physical examination of her chest, abdomen, back, and upper extremities revealed numerous, guttate, depigmented, porcelain-white macules with cigarette paper atrophy, subtle scale, and scattered excoriations (Figures 1A and 1B). Her neck had hypopigmented irregular macules with subtle scale. Two skin punch biopsies were obtained from lesions localized to her right upper chest and mid-back. Histolopathology demonstrated multiple short hyphae and spores in the stratum corneum (Figure 2) and Verhoeff-Van Gieson revealed mild elastolysis. These findings were consistent with atrophying tinea versicolor.

She was started on topical ketoconazole 2% shampoo three times weekly while her liver function tests were pending. Her tests returned within normal limits and she was started on a 2-week course of oral ketoconazole therapy. She subsequently had marked clinical improvement with a decrease in the number and size of atrophic lesions. She continued maintenance therapy with topical ketoconazole 2% shampoo once weekly.

Discussion

Tinea versicolor (TV) is a superficial cutaneous fungal infection caused by Malassezia, which is a dimorphic and lipophilic organism that resides in the stratum corneum. TV

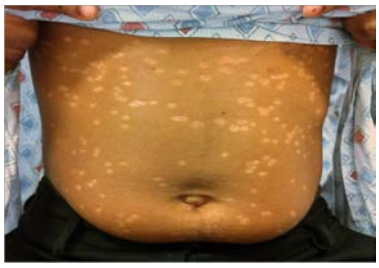

Figure 1A: Abdomen with numerous, guttate, depigmented, porcelain-white papules with cigarette paper atrophy, subtle scale, and scattered excoriations.



Figure 1B: Close-up of Figure 1A showing guttate, depigmented, porcelain-white papules with distinct atrophy.

 ***Corresponding author email:** *sailesh.konda@dermatology.med.ufl.edu*

Copyright:
© 2015 Konda et al.

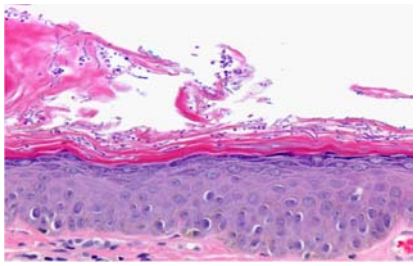

Figure 2: Histolopathology demonstrated multiple short hyphae and spores in the stratum corneum.

is common with a nationwide prevalence of 2-8%. Although difficult to culture, Malassezia globosa and Malassezia furfur are the two species predominantly isolated when cultured on media enriched with C12- to C14-fatty acids. Available growth mediums include Dixon's medium containing Tween 40 and glycerol-monooleate, and Leeming and Notman medium containing Tween 60, glycerol, and full-fat cow's milk. Patients usually present with numerous oval-to-round macules with fine scale scattered on the neck, trunk, and extremities. Predisposing factors include genetic susceptibility, humid environments, immunosuppression, malnutrition, and Cushing disease.

There have been at least 17 reports of TV associated with skin atrophy since 1971 (Table 1). These cases do not appear to have an age or sex predilection. A majority of cases documented atrophic lesions localized to the trunk and upper extremities. Notably, one of the cases reported granulomatous lesions localized to the eyelid, cheek, and nose. On histopathological evaluation, all cases with skin biopsies demonstrated poikilodermatous tissue alterations, which include loss of the epidermal retiform pattern, vascular ectasia, and thinning of dermal collagen bundles. Five of the cases, including ours, had evidence of elastolysis, which is not a requirement for diagnosis. Lastly, only four of the patients had a previous history of topical corticosteroid use.

Crowson and Magro coined the term 'atrophying tinea versicolor,' which should be considered one of the rare variants of TV [1]. Some cases of atrophying TV may be associated with a history of long-term topical corticosteroid use, which our patient did not have [2]. The link between topical steroids and the onset of atrophy may be causal or simply coincidental. Skin atrophy may also occur secondary to delayed-type hypersensitivity reactions, the direct effect of *Malassezia* on NF-κB signaling, or increased synthesis of pro-inflammatory cytokines, such as IL-1β and TNF-α [1]. Histopathology will reveal the classic short hyphae and spores in the stratum corneum as well as partial atrophy of the epidermis. Many cases have evidence of poikilodermatous tissue alterations [1]. Long-standing lesions may also demonstrate

Table 1: Clinical features.

Case No.[a]	Age/Sex	Clinical lesions	Location	Microscopic evidence of poikilodermatous tissue alterations[b]	Presence of elastolysis	Previous topical corticosteroid use
1 (current case)	26/F	atrophic macules	trunk, upper extremities	Yes	Yes	None
2	47/M	atrophic plaques	back	KOH only	KOH only	Yes, long-standing
3	55/M	Atrophic macules/patches	arms	Yes	No	None
4	50/M	atrophic macules/plaques	trunk, upper arm, buttock, thigh	Yes	Yes	Yes, long-standing
5	49/F	atrophic macules	arms, neck	Yes	Yes	None
6	17/F	atrophic macules	back, shoulders	Yes	Yes	Yes, single dose
7	55/F	atrophic patches	shoulders	Yes	Yes	None
8	19/F	atrophic plaques	trunk, shoulders	Yes	No	None
9	57/M	atrophic plaques	trunk, shoulders	Yes	No	None
10	21/M	atrophic patches	anterior chest	Yes	No	None
11	72/F	atrophic macules	forearm	Yes	No	None
12	58/F	granulomata	eyelid, cheek, nose	Yes	No	None
13	73/M	atrophic macules	chest	Yes	No	None
14	59/M	atrophic macules	site unspecified	Yes	No	Yes, long-standing
15	22/M	atrophic macules	left arm	Yes	No	None
16	25/F	atrophic macules	upper back	Yes	No	None
17	72/F	atrophic macules	back, shoulders	Yes	No	None

Table adapted from Crowson and Magro [1]
[a] Case 2 reported by Cullingham and Hall [4]. Case 3 reported by Park et al [5]. Case 4 reported by Yang et al [6]. Case 5 reported by Romano et al [7]. Cases 6-17 reported by Crowson and Magro [1].
[b]Poikilodermatous tissue alterations include loss of epidermal retiform pattern, vascular ectasia, and thinning of dermal collagen bundles.

Copyright:
© 2015 Konda et al.

dermal elastolysis, which may be due to histiocytes releasing elastase. Further studies are warranted to elucidate the precise mechanism of atrophy and to examine if certain species of *Malassezia* have a greater propensity to develop atrophic lesions. Understandably, these answers have been evasive due to the paucity of cases reported in the literature.

A possible mechanism of hypopigmentation in TV involves the yeast's production of azelaic acid, which inhibits tyrosinase. Additionally, TNF-α inhibits melanogenesis through the NF-κB pathway by down-regulating tyrosinase promoter activity [3]. Interestingly, kojic acid, used by our patient, is also an antityrosinase depigmenting agent found in skin-lightening cosmetic products used to treat hyperpigmentation and melasma. Theoretically, it is possible that the kojic acid used by our patient further enhanced tyrosinase inhibition. There are no documented reports of tinea versicolor, atrophying or otherwise, following topical application of kojic acid.

Atrophying TV should be added to the differential diagnosis of other atrophying conditions, such as anetoderma, atrophoderma of Pasini and Pierini, morphea, lupus erythematosus, dermatomyositis, parapsoriasis, mycosis fungoides, poikilodermatous T-cell dyscrasias, acrodermatitis chronic atrophicans, sarcoidosis, and cutis laxa. Previous reports document complete resolution of lesions, including atrophy, following courses of oral antifungal therapy. Prophylactic therapy may help reduce high recurrence rates.

References

1. Crowson AN, Magro CM. Atrophying tinea versicolor: a clinical and histological study of 12 patients. Int J Dermatol. 2003;42[12]:928-932.
2. Tatnall FM, Rycroft RJ. Pityriasis versicolor with cutaneous atrophy induced by topical steroid application. ClinExpDermatol. 1985;10[3]:258-261.
3. Englaro W, Bahadoran P, Bertolotto C , Buscà R, Dérijard B, Livolsi A, et al. Tumor necrosis factor alpha-mediated inhibition of melanogenesis is dependent on nuclear factor kappa B activation. Oncogene. 1999;18[8]:1553-1559.
4. Cullingham K, Hull PR. Atrophying pityriasis versicolor. CMAJ. 2014;186[10]:776. doi:10.1503/cmaj.131846
5. Park JS, Chae IS, Kim IY, Ko DK, Chung H, Lee SW. Achromatic atrophic macules and patches of upper extremities. Indian J DermatolVenereolLeprol. 2013;79[2]:270. doi: 10.4103/0378-6323.107677.
6. Yang YS, Shin MK, Haw CR. Atrophying pityriasis versicolor: is this a new variant of pityriasis versicolor? Ann Dermatol. 2010;22[4]:456-459.
7. Romano C, Maritati E, Ghilardi A, Miracco C, Mancianti F. A case of pityriasis versicolor atrophicans.Mycoses. 2005;48[6]:439-441.