

# Diagnosis and Management of Infective Endocarditis in Patient with Ventricular Septal Defect: A Report of Clinical Case from Dakar, Senegal

Mohamed Leye<sup>1</sup>, Momar Dioum<sup>2</sup>, Adama Sawadogo<sup>3\*</sup>, Modibo Doumbia<sup>3</sup>, Joseph Mingou<sup>4</sup>, Dominique Bindia<sup>2</sup>, Arame Diagne Diallo<sup>2</sup>, Magalie Kaya<sup>2</sup>, Simon Manga<sup>2</sup>, Kadia Ba<sup>2</sup>, Ousmane Dieye<sup>2</sup> and Ibrahima Bara Diop<sup>2</sup>

<sup>1</sup>Department of Cardiology, Unit of Training and Research in medical sciences, University of Thies, Senegal

<sup>2</sup>Department of Cardiology, Hospital of Fann, Cheikh Anta DIOP University of Dakar, Senegal

<sup>3</sup>Department of Thoracic and Cardiovascular Surgery, Hospital of Fann, Cheikh Anta DIOP University of Dakar, Senegal

<sup>4</sup>Department of Cardiology, Aristide Le Dantec Hospital, Cheikh Anta DIOP University of Dakar, Republic of Senegal

Received: 16 March, 2017 ; Accepted: 22 April, 2017; Published:02 May, 2017

\*Corresponding author: Adama Sawadogo, MD, Department of Thoracic and Cardiovascular Surgery, Hospital of Fann, Cheikh Anta DIOP University of Dakar, Senegal, E-mail: adamsaw2000@yahoo.fr

## Abstract

Infective Endocarditis (IE) due to Streptococcus pneumoniae is a rare serious complication in the patients with congenital heart diseases. The authors report a case of pneumococcal endocarditis in a 13-year-old boy diagnosed with VSD.

**Keywords:** Endocarditis; Ventricular septal defect; Streptococcaceae; Antibiotic therapy

## Introduction

Infective Endocarditis (IE) is an infective inflammation of the endocardium leading mainly to valvular damage and causing significant mortality and morbidity. It can occur on healthy or pathological heart [1]. Endocarditis due to Streptococcus pneumoniae is unusual in children, accounting for 3%–7% of all cases of childhood endocarditis. It is a serious complication of congenital heart diseases [2,3]. We report a case of IE due to streptococcus pneumoniae in 13-year-old boy diagnosed with VSD.

## Case Report

MT is a 13-year-old boy who presented in our department with intermittent fever that was highest on late afternoon associated with anorexia and worsening of his physical status. Regarding his previous medical history, he was born from a normal pregnancy without parental consanguinity. Then he was diagnosed with VSD at the age of 6-year-old. The clinical examination found a fever at 39.1°C and a purring thrill at the palpation of the cardiac area. On auscultation, heart sounds were regular; there was pansystolic murmur with isometric

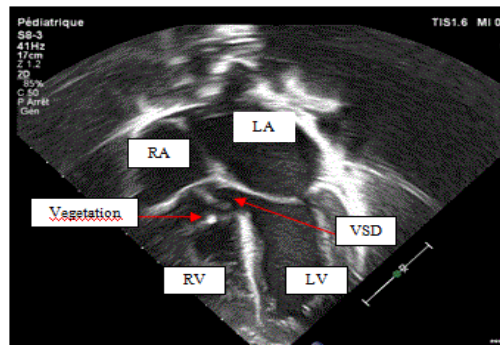


Figure 1: TTE 5-cavity apical view: 2D mode showing VSD and vegetation (red arrows)

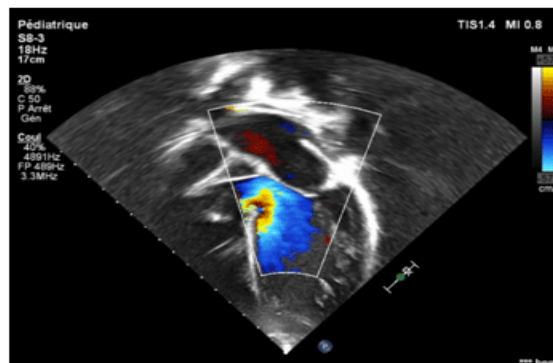


Figure 2: TTE 5-cavity apical view: Color mode showing the same findings with left to right shunt

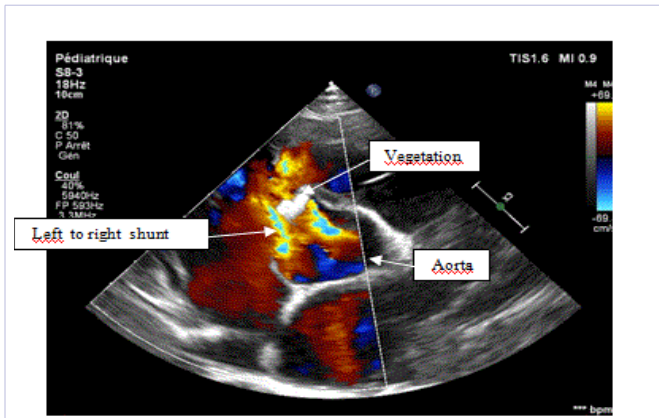


Figure 3: TTE Short axis parasternal view color mode showing vegetation and shunt

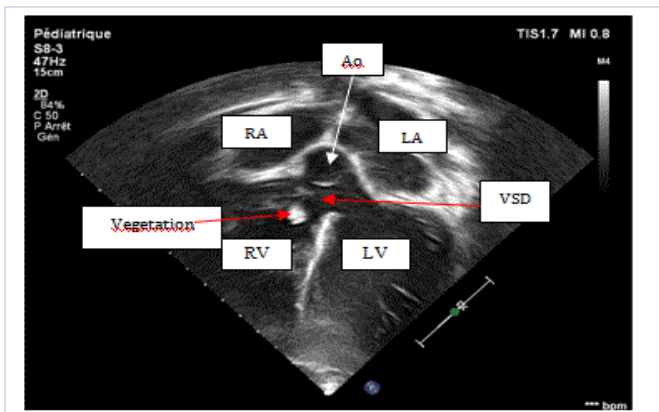


Figure 4: TTE 5-cavity view 2D mode: showing subaortic VSD and vegetation

handgrip. Pulmonary examination was normal. No dental or ENT area infection was found. The chest X-rays showed a bilateral hilar vascular overload. The electrocardiogram (ECG) showed a regular sinus tachycardia with heart rate at 116 bpm with a right axis heart. Transthoracic Echocardiogram (TTE) confirmed the VSD which was perimembranous with 16 mm diameter. Vegetation could be seen on the right side of the VSD. They were attached to the edge of the defect and infundibulum (Figures 1 to 4). Left Ventricle end-diastolic and end-systolic diameters were 55 and 30 mm respectively and ejection fraction was 74%. At biology, CRP raised up to 97 mg/dL with hyperleukocytosis at 11,000 white blood cells / mm<sup>3</sup>. The test for malaria (blood smear) was negative. Empiric antibiotic therapy was started and included gentamicin 2.5 mg/kg for 5 days associated with ceftriaxone 50 mg/kg for 21 days before laboratory microbiological reports are available. There was improvement of the clinical feature at the first week with normalized temperature and drop in CRP (16 mg/dL). However, on week 3 the fever appeared again and CRP rose to 48 mg/dL. Finally, blood cultures isolated *Streptococcus pneumoniae* that was resistant to penicillin and ceftriaxone but sensitive to vancomycin, linezolid, pristinamycin and imipenem. The laboratory did not determine the minimum inhibitory concentration (MIC). Urine culture was negative.

Then we prescribed vancomycin 15 mg/kg IV for 36 more days. On day 57, CRP was at 8 mg/dl, the control TTE found persisting vegetation. The total duration of IV antibiotics was 57 days. The patient was discharged from hospital with a good clinical condition. A surgical repair is to be planned after total sterilization of the IE.

## Discussion

Pneumococcal endocarditis has become uncommon since the advent of penicillin; it now develops in less than 1% of native heart valves and that the vast majority (91%) of children with pneumococcal endocarditis have underlying structural heart disease [4,5]. Rheumatic valve disease is the most common cardiac pathology in the developing countries [3]. It is known that VSD is the most common malformation. Some studies found that patients with VSD were six times more likely to suffer from IE compared to the general population [1,6]. TTE or TEE are useful for diagnosis and follow-up of IE [7,2]. TEE is recommended in patients with prosthetic valve or other intra-cardiac material in case TTE is not contributive [8]. The diagnosis is based on the modified Duke University criteria [9]. According to these criteria, IE is certain if microorganisms are found in blood culture or histology of vegetation or in intra-cardiac abscess. Another diagnosis is based on the presence of vegetation or intra-cardiac abscess associated with histological confirmation of an evolving IE. We had isolated the streptococcus. This germ was also preponderant in some studies such as the series of Li et al. who found 56% Viridans streptococci in a series of 130 VSD-patients with IE [10]. No source was found over clinical examination and other investigations but in the literature, dental infection, ENT source, open-heart surgery, cutaneous wound and catheterization are reported [10]. Like our patient, the treatment of IE in case of positive blood culture is primarily based on a targeted antibiotic therapy in monotherapy or in combination. Practically, the intravenous route should be considered as the reference because it ensures total bioavailability [1]. During antibiotic treatment, disappearance of fever and the remaining normal temperature, negative blood culture and disappearance of biological inflammation syndrome are the best guarantee of the efficiency of antibiotic therapy. The duration of the association should be 2 weeks and the total duration of treatment should last 4 weeks or up to 6 weeks in case of prolonged evolution or complicated form. Surgical treatment remains inaccessible for most children with congenital heart diseases in our context. About 22% of the patients required surgery in the series of Givner (11 patients) [4]. Although the stabilized situation of our patient, surgical repair is to be performed as soon as possible to avoid embolic accidents and to reduce the risk of mortality. The purpose of this article is to discuss the prevention of IE in the case of VSD. According to 2015 guidelines, antibiotic prophylaxis is not recommended for high-risk cardiac diseases. The National Institute of Excellence in Health and Care (NICE 2008) went even further by not recommending antibiotic prophylaxis regardless of cardiac history and procedure. In addition, antibiotic therapy exposes the risk of anaphylaxis and the emergence of resistant strains [11,12]. The question is whether these recommendations

can really be applied in the developing countries that are lacking asepsis measures? The Adult Expert Panel for the Hospital Level which is a part of the National List of Essential Medicines Committee of South Africa recommends antibiotic prophylaxis in Osler infections, for high-risk procedures even in patients with acquired valve diseases [13]. The definitive answer requires controlled randomized studies which is tricky due to the large number of patients to include. In our opinion, it is reasonable to apply the recommendations of international societies but in taking into consideration the socio-economic context, the expertise in dentistry but also the microbiological environment of each region; the antibiotic prophylaxis in case of VSD is not necessary [11,1].

## Conclusion

IE due to streptococcus pneumoniae is a rare clinical situation in VSD-patients that is not reported within our region yet. In our context, echocardiogram associated with blood culture can make the diagnosis. A well managed antibiotic therapy is a key to stabilize the infection prior to perform surgical repair.

## References

1. Boussir H, Ghalem A, Ismaili N, El Ouafi N. Endocardite infectieuse sur communication interventriculaire: intérêt de l'échocardiographie? De l'antibioprophylaxie? *Pan Afr Med J.* 2016;25:154 . doi:10.11604/pamj.206.25.154.10673
2. Hosseini MT, Quarto C, Bahrami T. Quadruple-valve infective endocarditis and ventricular septal defect. *Tex Heart Inst J.* 2013;40(2):209-210.
3. Lacalzada J, Padilla M, De la Rosa A, Laynez I. Infectious endocarditis due to *Streptococcus pneumoniae* in a cardiac surgery patient: a new form of clinical presentation. *Clin Case Rep.* 2016;4(2):129-132. doi: 10.1002/ccr3.448
4. Givner LB, Masson EO, Tan TQ, Barson WJ, Schutze GE, Wald ER, et al. Pneumococcal Endocarditis in Children. *Clin Infect Dis.* 2004;38(9):1273-1278. doi: 10.1086/383323
5. Jorge C, Marques JS, Nobre A, Correia MJ, Diogo AN. Perimembranous ventricular septal defect vegetation in a patient with right- and left-sided infective endocarditis. *Rev Port Cardiol.* 2013;32(11):951-952. doi: 10.1016/j.repc.2013.04.012
6. Li W, Somerville J. Infective endocarditis in the grown-up congenital heart (GUCH) population. *Eur Heart J.* 1998;19(1):166-173.
7. Ben-Chetrit E, Weiner-Well Y, Katz DE, Rosenman D, Munter G. VSD-associated right sided infective endocarditis complicated by septic pulmonary emboli. *Am J Med Sci.* 2016;352(1):107-108. doi: 10.1016/j.amjms.2016.03.007
8. Delahaye F, Vandenesch F, Hoen B, Loire R, Delahaye J-P. Endocardite infectieuse. *Encycl Med Chir Cardiol.* 2006;11-013-B-10.
9. Durack DT, Lukes AS, Bright DK and the Duke Endocarditis Service. New criteria for diagnosis of infective endocarditis: utilization of specific echocardiographic findings. *Am J Med.* 1994;96(3):200-209.
10. Li JS, Sexton DJ, Mick N, Nettles R, Fowler Jr. VG, Ryan T, et al. Proposed modifications to the Duke criteria for the diagnosis of infective endocarditis. *Clin Infect Dis.* 2000;30(4):633-638. doi: 10.1086/313753
11. Chirillo F, Faggiano P, Cecconi M, Moreo A, Squeri A, Gaddi O, et al. Predisposing cardiac conditions, interventional procedures, and antibiotic prophylaxis among patients with infective endocarditis. *Am Heart J.* 2016;179:42-50. doi: 10.1016/j.ahj.2016.03.028
12. Breminand M, Andrew P. Prevention of infective endocarditis in developing countries. *Cardiovasc J Afr.* 2012;23(6):303-305. doi: 10.5830/CVJA-2012-004
13. Habib G, Lancellotti P, Antunes MJ, Bongiorni MG, Casalta JP, Del Zotti F, et al. 2015 ESC Guidelines for the management of infective endocarditis. *Rev Esp Cardiol.* 2016; 69(1): 69.